



**GUIDELINE**

**Gastroschisis**

<b>Scope (Staff):</b>	Nursing and Medical Staff
<b>Scope (Area):</b>	NICU KEMH, NICU PCH, NETS WA

**Child Safe Organisation Statement of Commitment**

CAHS commits to being a child safe organisation by applying the National Principles for Child Safe Organisations. This is a commitment to a strong culture supported by robust policies and procedures to reduce the likelihood of harm to children and young people.

**This document should be read in conjunction with this [disclaimer](#)**

Also refer to [NETS WA Guideline: Surgical Conditions](#).

**Contents**

Aim ..... 2

Risk..... 2

Definitions ..... 2

Key points ..... 2

Antenatal Management Prior to Birth at KEMH ..... 2

Management at Birth in Labour Ward at KEMH ..... 2

Management on Admission to SCN3 at KEMH ..... 3

General management of a gastroschisis infant with a silo ..... 4

Surgical Closure of Gastroschisis ..... 5

Post-operative management following complete closure, either after silo or after primary closure ..... 5

    Pain Management ..... 6

    Mechanical Ventilation..... 6

    Fluid and electrolyte balance ..... 6

    Gastric Losses..... 6

    Decreased urinary output ..... 6

    Antibiotics ..... 7

    Nutrition..... 7

    Discharge planning and follow up ..... 7

## Aim

To achieve optimal outcomes for neonates with gastroschisis.

## Risk

Not adherence carries a risk of result in gut necrosis, dehydration, and other morbidities in babies with gastroschisis.

## Definitions

- Gastroschisis is a congenital anomaly characterised by a full thickness abdominal wall defect, usually just to the right of an intact umbilical cord, through which a variable amount of intestine protrudes without a covering membrane. Other abdominal viscera like liver, spleen, gonads etc. may also protrude through the defect.
- Classified into simple and complex types based on the condition of the bowel at birth.
  - In simple gastroschisis, the bowel is in good condition at birth with no intestinal complications.
  - Complex gastroschisis, on the other hand, is associated with congenital intestinal complications in the form of an atresia, perforation, ischemia, necrosis, or volvulus. Infants with complex gastroschisis have higher rates of mortality, morbidity and prolonged feed intolerance compared to simple gastroschisis. This information needs to be considered while counselling parents.

## Key points

- Prevention of dehydration and hypothermia immediately after birth
- Careful observation of the gut in silo for signs of ischaemia
- Careful observation in the postoperative period for signs of abdominal compartment syndrome.
- Contacting the surgeons and neonatologist at the slightest suspicion of gut ischemia or compartment syndrome.

## Antenatal Management Prior to Birth at KEMH

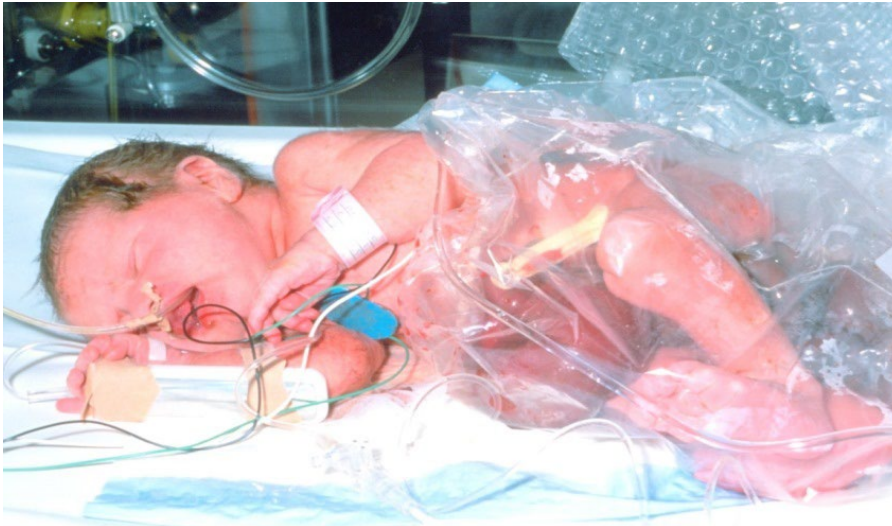- **Liase with the on-call Paediatric Surgeons and NICU 3B before birth of the baby (if the diagnosis of gastroschisis is known).** The paediatric surgeons may wish to be present at KEMH soon after the birth in order to place the exposed bowel into a silo before the baby is transferred to PCH NICU 3B. PCH NICU 3B may need to make room for the admission by moving existing infants.

## Management at Birth in Labour Ward at KEMH

- Standard neonatal resuscitation as per NRP guidelines.

- **Double bagging using sterile plastic bags:** the first bag covers the legs and lower abdomen i.e. secured just below the exposed bowel to prevent the bowel being soiled by urine and meconium; and then the second bag covers the first bag and exposed bowel and is secured above the bowel close to the axilla. This protects the bowel and reduces heat and fluid losses and allows for ongoing careful inspection of the bowel for discolouration.

**Note:** Cling film can be loosely wrapped around the baby when a bowel bag is not available.



- Lay the infant on the same side as the defect for transport to NICU. Note: most defects are on the right side This will prevent kinking of the bowel and compromising the blood supply.
- Insert size 8Fg oro-gastric tube and fully aspirate the stomach contents and leave on free drainage. If the stomach is

## Management on Admission to SCN3 at KEMH

- Immediately upon admission to NICU, contact PCH NICU, NETS WA and the surgical team and confirm that delivery has occurred. If the surgeon is unable to attend the infant at KEMH, arrange for transfer to PCH NICU as soon as the infant is stable for transport.
- Nurse the infant under a radiant warmer. The infant's legs and torso should remain inside the impermeable bowel bags in order to limit fluid and heat loss from the bowel and also to allow easy inspection of the bowel and help protect the bowel and limit the risk of sepsis.
- Insert size 8Fg oro/nasal gastric tube if not inserted at delivery and fully aspirate the stomach contents and leave on free drainage. Watch for bile aspirates.
- Watch bowel colour and report any discolouration that develops; repositioning the bowel relative to the abdominal opening maybe necessary if the bowel

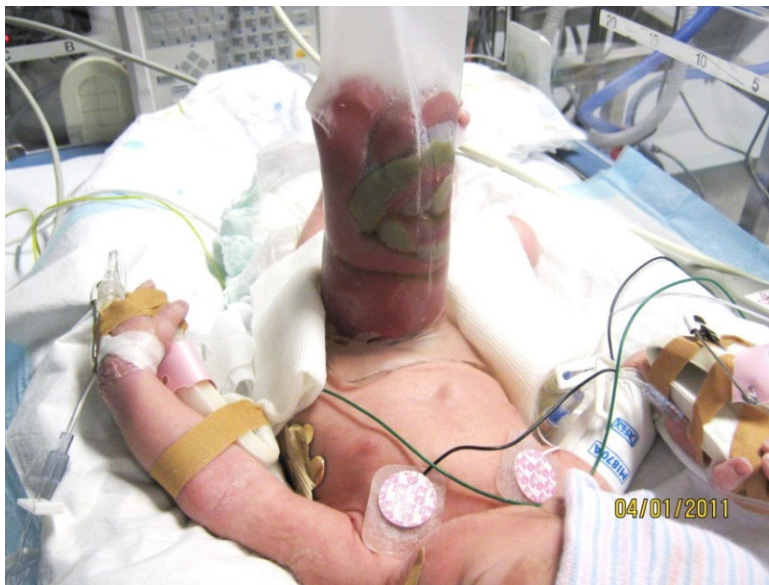becomes dusky. Request an urgent surgical review if there is no improvement in the colour of the bowel.

- Insert an IV cannula and commence maintenance fluids (7.5 to 10% glucose) at 80 mL/kg/day in neonates > 37 weeks gestation and 100 mL/kg/day in preterm infants.
  - **In addition**, commence an infusion of **Normal Saline at a rate of 10 mL/kg/hr**. The Normal Saline infusion should continue until the surgeons apply a silo or until a formal reduction of gastroschisis is achieved (whichever happens first).
  - **Once the Silo is applied make sure to stop the Normal Saline infusion.**
- It may be necessary to give additional boluses of Normal Saline if hypoperfusion, hypotension, or metabolic/lactic acidosis is present. Consider early use of inotropes (Dopamine or Dobutamine) if no improvement with Normal saline infusion/boluses.
- Give IV prophylactic antibiotic [Tazocin \(Piperacillin plus Tazobactam\)](#) after collecting blood cultures.
- Examine the infant for associated anomalies.
- FBC, blood group and hold or crossmatch, blood gas, blood culture. **Ensure that 10mLs of clotted maternal blood for cross-matching is collected.**
- Once the baby is stable, transfer to PCH NICU 3B.

## General management of a gastroschisis infant with a silo

- Nil oral and keep the stomach on free drainage with a large bore catheter.
- Discuss with senior registrar or consultant regarding commencement of parenteral nutrition.
- Extra IV fluids will be required if gastric losses are greater than 10 mLs/kg/12hour period. The total fluid loss in the previous 12-hour period should be replaced (half as TPN solution and half as Normal Saline via a sideline). Refer to [Replacement of Gastrointestinal Fluid Losses in Surgical Neonates](#).
- Surgeons will gradually reduce the intestinal contents as the baby's condition permits, usually over 2-5 days.
- Where necessary, provide analgesia (low dose [morphine](#) infusion or IV [paracetamol](#)). Usually, babies with gastroschisis are reasonably comfortable with minimal or no pain while the intestinal contents are in a silo. If high doses of morphine are needed, endotracheal intubation and ventilation may be necessary.
- Carefully observe the bowel for discolouration. Normal bowel in silo should look pink. Grey, purple or black looking bowel indicates vascular compromise. This

situation should be reviewed immediately by senior neonatal staff and surgeons.



## Surgical Closure of Gastroschisis

- Due to the absence of large RCTs, there is debate about the ideal surgical method for closure of gastroschisis (immediate primary closure vs silo followed by delayed closure). The usual approach at KEMH/PCH is staged closure using a silo.
- Our own experience of 110 babies in the recent 10 years using this approach has been reassuring with excellent results with staged reduction using silo (results due for presentation and publication) compared to international benchmarks.
- Occasionally, primary closure of the defect is undertaken. The surgical consultants will decide on the type of closure, in discussion with the neonatal team.

## Post-operative management following complete closure, either after silo or after primary closure

Some infants may not adapt quickly to the extra amount of gut which has been reduced into the abdominal cavity. This could result in compression of the mesenteric blood vessels leading to ischemia of the bowel. This is called “**abdominal compartment syndrome**”. If this is not diagnosed and treated quickly, it can have catastrophic consequences, such as necrosis of the bowel. One or more of the following clinical features should suggest the possibility of abdominal compartment syndrome:

- A significant increase in ventilator pressures compared to the pre-reduction pressures.
- Tense and tender abdomen.

- Discolouration of abdominal wall and lower limbs.
- Very high morphine requirements.
- Progressive worsening of metabolic and or respiratory acidosis, high lactate levels.
- Hypotension requiring inotropic support.
- Decreased or absent urine output.

If one or more of these clinical features develop, you should seek an **urgent** senior neonatal review and contact the surgical team.

## Pain Management

Analgesia should be provided as needed, preferably with intravenous Paracetamol or Morphine. A balance should be maintained between effective analgesia and side effects of opiates on respiratory depression and gut motility. Normally infants with a silo do not require significant analgesia. If an infant needs high dose morphine infusions, it should alert the clinicians to the possibility of bowel ischemia.

## Mechanical Ventilation

Usually, infants with gastroschisis do not need mechanical ventilation while the intestinal contents are in silo. Occasionally, if the infant is in significant pain, higher doses of narcotic analgesics may be required, necessitating endotracheal intubation and mechanical ventilation. Use cuffed endotracheal tube (size 3.0) if possible. Otherwise, standard uncuffed ETT is also appropriate to use. Aim to extubate the infant as soon as feasible after surgery (usually within 24-48 hours after surgery).

## Fluid and electrolyte balance

Frequent blood gas and electrolyte measurements (6-12 hourly) should be performed to guide fluid therapy. Blood pressure, capillary refill, pulse rate, colour, amount of gastric aspirates and urine output should be taken into consideration in adjusting fluid therapy.

## Gastric Losses

Refer to [Fluid replacement therapy for surgical neonates](#)

A large bore gastric tube (size 8 or 10Fg) on free drainage with 1-2 hourly gentle aspirations is needed to prevent gastrointestinal distension caused by post-operative ileus and the reduction process. Monitoring and replacement of losses is necessary as some infants can lose very large volumes of stomach fluids. Losses are generally replaced as normal saline and TPN (50:50) but are tailored to the baby's electrolyte status. In some cases, this may last for weeks until gut motility improves.

## Decreased urinary output

A decrease in urine output may be due to renal venous compression as a result of the raised intra-abdominal pressure or an inadequate intravascular volume (due to inadequate fluid loss replacement or 'third' spacing). **Bladder retention** is a frequent



problem, often as a side effect of morphine analgesia. A urinary catheter may be necessary.

## Antibiotics

Antibiotics are routinely started immediately after birth and usually continued until the abdominal wall defect is closed.

Routine antibiotic therapy is with [Piperacillin Tazobactam](#). [Vancomycin](#) is to be used if there is significant abdominal wall redness or late onset sepsis is suspected.

Whilst it is reasonable to monitor CRP levels whilst on antibiotics, clinicians need to be aware that CRP may be elevated due to the underlying inflammatory process in gastroschisis or due to surgical injury

## Nutrition

- Consider early placement of a percutaneous long line. Consider commencing parenteral nutrition once the baby is stable.
- Enteral feeding is to be commenced in the postoperative period as soon as the infant is stable. Expressed breastmilk of mum is the preferred type of milk. Early initiation of enteral feeding has the potential to improve the gut function in babies with gastroschisis and hence improved feed tolerance.
- Trophic feeds are often given even when there are relatively large gastric aspirates.
- Enteral feeds are increased as tolerated, as judged by the amount of gastric aspirates/vomits, abdominal distension and bowel actions.
- Occasionally, gut dysmotility can persist for many weeks, especially in complex gastroschisis and longer term TPN may be needed.

## Discharge planning and follow up

Ensure all follow ups are booked (e.g. surgical, neonatal, and developmental) prior to discharging the infant.

### Related CAHS internal policies, procedures and guidelines

- [Surgical Conditions \(health.wa.gov.au\) \(NETS WA\)](#)
- Resuscitation
- Sepsis
- [Medication Monographs](#)

### References and related external legislation, policies, and guidelines


1. Bhat V, Moront M, Bhandari V. Gastroschisis: A State-of-the-Art Review. Children (Basel). 2020 Dec 17;7(12):302.

2. Bergholz R, Boettcher M, Reinshagen K, Wenke K. Complex gastroschisis is a different entity to simple gastroschisis affecting morbidity and mortality-a systematic review and meta-analysis. J Pediatr Surg. 2014 Oct;49(10):1527-32.
3. Petrosyan M, Sandler AD. Closure methods in gastroschisis. Semin Pediatr Surg. 2018 Oct;27(5):304-308
4. Dama M, Rao U, Gollow I, Bulsara M, Rao S. Early Commencement of Enteral Feeds in Gastroschisis: A Systematic Review of Literature. Eur J Pediatr Surg. 2017 Dec;27(6):503-515.
5. Poola AS, Aguayo P, Fraser JD, Hendrickson RJ, Weaver KL, Gonzalez KW, St Peter SD. Primary Closure versus Bedside Silo and Delayed Closure for Gastroschisis: A Truncated Prospective Randomized Trial. Eur J Pediatr Surg. 2019 Apr;29(2):203-208
6. Slidell MB et al. Management of Gastroschisis: Timing of Delivery, Antibiotic Usage, and Closure Considerations (A Systematic Review From the American Pediatric Surgical Association Outcomes & Evidence Based Practice Committee). Pediatr Surg. 2024 Apr 30:S0022-3468(24)00198-2.
7. Ferreira RG et al Gastroschisis: a systematic review of diagnosis, prognosis and treatment. J Matern Fetal Neonatal Med. 2022 Dec;35(25):6199-6212.

### Useful resources (including related forms)

[Replacement Of Gastrointestinal Fluid Losses In Surgical Neonates](#)

This document can be made available in alternative formats on request.

Document Owner:	Neonatology		
Reviewer / Team:	Neonatal Coordinating Group		
Date First Issued:	August 2008	Last Reviewed:	June 2024
Amendment Dates:		Next Review Date:	June 2027
Approved by:	Neonatal Coordinating Group	Date:	25 <sup>th</sup> June 2024
Endorsed by:	Neonatal Coordinating Group		
Standards Applicable:	NSQHS Standards:  Child Safe Standards: 1,10		

Printed or personally saved electronic copies of this document are considered uncontrolled



## Healthy kids, healthy communities

Compassion

Excellence

Collaboration

Accountability

Equity

Respect

Neonatology | Community Health | Mental Health | Perth Children's Hospital