



CLINICAL GUIDELINE

Patent Ductus Arteriosus (PDA)

Scope (Staff):	Nursing and Medical Staff
Scope (Area):	NICU KEMH, NICU PCH, NETS WA

This document should be read in conjunction with this [DISCLAIMER](#)

The ductus arteriosus is a large vessel that connects the main pulmonary trunk with the descending aorta. In utero pulmonary resistance remains high and only 7-10% of the combined cardiac output is directed through the right and left pulmonary arteries. The bulk of the right ventricular output travels through the ductus arteriosus maintaining flow in the descending aorta and hence placental perfusion.

At delivery a series of complex changes occur as an orchestrated continuum. With the first breath pulmonary capillaries open and resistance to pulmonary blood flow drops. This leads to further reduction in right sided pressures and directs the right ventricular output through the pulmonary circulation. As systemic pressures start to exceed pulmonary pressures, blood flow through the ductus arteriosus reverses and oxygenated blood from the systemic circulation flows into the pulmonary circulation. Final functional closure occurs by 24 hours of age in around half of healthy full-term infants but may be considerably delayed in the premature.

Presentation

A DA is usually clinically silent over the first couple of days of life. Echocardiography may however reveal a significant left to right shunt with reverse flow in diastole in the major blood vessels, ductal steal. As pulmonary vascular resistance continues to drop the left to right shunting will increase and the DA may become clinically apparent with a cardiac murmur and increased pulse pressure. Continuing patency of the DA may lead to later heart failure and respiratory symptoms. Occasionally, a widely patent DA can lead to acute cardiac failure, ductal steal with impaired cardiac output, resulting in poor peripheral perfusion, metabolic acidosis and shock.

Treatment

The clinical management of the DA is still a topic of hot debate despite several hundred publications and many clinical trials. Prophylactic treatment with indomethacin has been well studied and shown to decrease IVH but not to confer long term neurodevelopmental advantage.¹⁻⁴ This practice is not widely adopted.

Some units have adopted the alternate extreme with the view that the DA is an innocent bystander and that there are no advantages in treating.⁵ We have adopted the “targeted” approach to the DA whereby treatment is determined by early echocardiography providing the early clinical advantages of prophylaxis without exposing infants at minimal risk from PDA to unnecessary medication. This approach was evaluated in a randomised trial (DETECT)⁶ in which treated infants with early echocardiographically significant DA had better short-term outcomes.

DA in near-term or term infants or in association with an anatomical/structural anomaly should be managed in conjunction with paediatric cardiology. Patients with a haemodynamically-significant DA should be regularly reviewed for evidence of cardiac failure and if present consideration should be given to treating the DA medically or surgically, in consultation with cardiology.

Principles of Management

The NSAID available in this unit is indomethacin. Ibuprofen has been used in the past but is no longer available. Paracetamol has been used with some success and can be considered as an alternative when indomethacin is contraindicated.

A Targeted Approach is Recommended

This is for infants < 28 weeks of gestation with treatment determined by an echo in the first 24 hours of life. Normal cardiac anatomy should be confirmed. Those with a DA > 1.5mm and/or evidence of ductal steal are targeted for treatment. If the findings are equivocal the echo should be repeated after 12 to 24 hours. Treatment is as per our Medication Protocols.

Indomethacin

The dose of [indomethacin](#) remains controversial with regimes ranging from 100 micrograms 24 hourly to 1000 micrograms 12 hourly. Published literature describes both a clear advantage and no advantage from escalating dosage. Sperandio et al⁷ documented a closure rate of > 98% with no increase in side effects while using a regime escalating to 1000 micrograms 12 hourly. In a similar sized study Jagatheesan⁸ et al could not demonstrate an advantage of 500 micrograms daily over 100 micrograms daily. Others have considered an area under the curve approach for indomethacin dosing. Independent analyses of pharmacokinetics and pharmacodynamics have suggested a critical total dose of 1000 micrograms to obtain a closure rate of 90% with minimal toxicity.⁹ It is therefore difficult to clearly recommend a dosage regime.

Initial dose of Indomethacin 200 micrograms followed by 100 or 200 micrograms per dose every 24 hours. A repeat echocardiogram should be performed within 24 hours of the third dose and a further 2 doses of indomethacin given if the DA remains patent.

Indomethacin impairs renal perfusion and reduces urine output, the drug is therefore contraindicated in renal failure. Indomethacin reduces platelet adhesiveness and is therefore contraindicated in thrombocytopenia (platelets < 60) or in infants with hypocoagulation. Indomethacin is not a contraindication to feeding.

If the DA remains patent a second course of indomethacin may be used, preferably at the higher dose. Infants are very unlikely to respond to a third course.

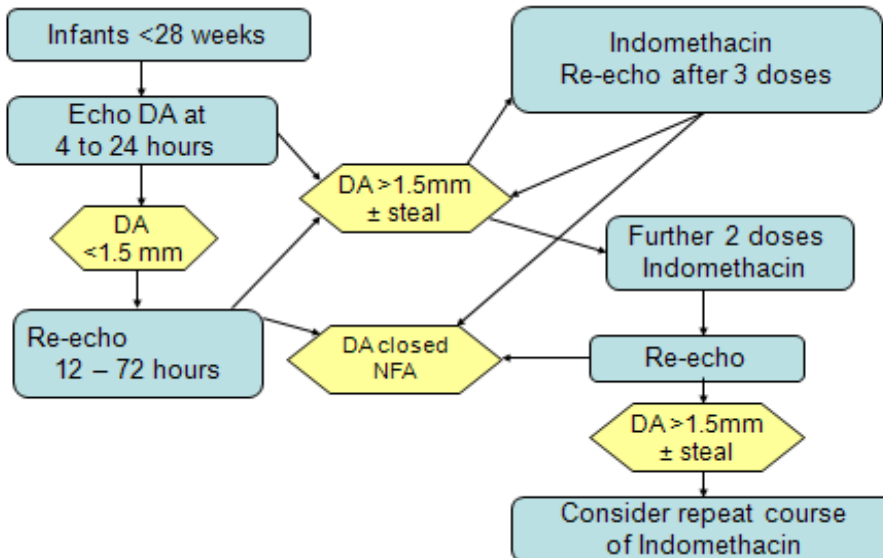
Paracetamol

There is growing evidence for the efficacy of [paracetamol](#) in DA closure but no evidence to suggest superiority to indomethacin⁽¹¹⁻¹³⁾. Paracetamol has, however, not been shown to protect against IVH and indomethacin is therefore the preferred drug for an initial course. The safety profile of paracetamol may be better than indomethacin and it may be considered when indomethacin is contraindicated. Paracetamol may also be considered as an oral course in infants who have previously not responded to indomethacin. A five day course of 15mg/Kg 6 hourly is recommended. There are a couple of worrying reports linking antenatal acetaminophen with behavioural disorders and some murine work to suggest plausible pathways⁽¹⁴⁾.

Surgical Ligation

Surgical ligation of the premature DA appears to confer more risk than benefit and is only considered on a case by case basis and after extensive consultation.

Flowchart for Management of DA



Ductus arteriosus and pulmonary hypertension

In infants with raised pulmonary pressures (hypoxic respiratory failure, significant R to L shunting across a DA a patent ductus arteriosus may help relieve pressure on the RV and should not be closed. Consideration should be given to maintaining DA patency in these circumstances with [Alprostadil- \(Prostaglandin E1\)](#). Use of iNO may also potentiate DA patency and NSAIDs or paracetamol are contraindicated while on NO.

Related CAHS internal policies, procedures and guidelines

Neonatal Medication Protocols:



- [Alprostadil- \(Prostaglandin E1\)](#)
- [Indomethacin](#)
- [Paracetamol](#)

References

1. Ment, L., et al., Outcome of children in the indomethacin intraventricular hemorrhage prevention trial. *Pediatrics*, 2000. 105(3): p. 485-491.
2. Ment, L., et al., Neurodevelopmental outcome at 36 months corrected age of preterm infants in the multicenter indomethacin intraventricular hemorrhage prevention trial. *Pediatrics*, 1996. 98(4): p. 714-18.
3. Schmidt, B., et al., Long term effects of indomethacin prophylaxis in extremely low birth weight

- infants. *New England Journal of Medicine*, 2001. 344(26): p. 1966-72.
4. Fowlie, P.W., P.G. Davis, and W. McGuire, Prophylactic intravenous indomethacin for preventing mortality and morbidity in preterm infants. *Cochrane Database Of Systematic Reviews (Online)*, 2010.
 5. Bose, C.L. and M.M. Laughon, Patent ductus arteriosus: lack of evidence for common treatments. *Arch. Dis. Child. Fetal Neonatal Ed.*, 2007. 92(6): p. F498-502.
 6. Kluckow, M., et al., A randomised placebo-controlled trial of early treatment of the patent ductus arteriosus. *Archives of Disease in Childhood - Fetal and Neonatal Edition*, 2013. 99: p. F99 - 104.
 7. Sperandio, M., et al., Effectiveness and side effects of an escalating, stepwise approach to indomethacin treatment for symptomatic patent ductus arteriosus in premature infants below 33 weeks of gestation. *Pediatrics*, 2005. 116(6): p. 1361-6.
 8. Jegatheesan, P., et al., Increased Indomethacin Dosing for Persistent Patent Ductus Arteriosus in Preterm Infants: A Multicenter, Randomized, Controlled Trial. *J Pediatr*, 2008. 153(2): p. 183 - 189.
 9. Shaffer, C.L., et al., Effect of age and birth weight on indomethacin pharmacodynamics in neonates treated for patent ductus arteriosus. *Critical Care Medicine*, 2002. 30(2): p. 343 - 348.
 10. Noori, S., Pros and cons of patent ductus arteriosus ligation: hemodynamic changes and other morbidities after patent ductus arteriosus ligation. *Seminars in perinatology*, 2012.36(2):p.139-45.
 11. EL-Khuffash, A., et al. (2015). "Late medical therapy of patent ductus arteriosus using intravenous paracetamol." *Archives of Disease in Childhood-Fetal and Neonatal Edition* 100(3): F253-F256.
 12. Harkin, P., et al. (2016). "Paracetamol Accelerates Closure of the Ductus Arteriosus after Premature Birth: A Randomized Trial." *Journal of Pediatrics*, The 177: 72-77 e72.
 13. Ohlsson, A. and P. S. Shah (2015). "Paracetamol (acetaminophen) for patent ductus arteriosus in preterm or low-birth-weight infants." *Cochrane Database Syst Rev*(3): CD010061.
 14. Stergiakouli, E., et al. (2016). "Association of Acetaminophen Use During Pregnancy With Behavioral Problems in Childhood: Evidence Against Confounding." *JAMA Pediatr* 170(10): 964-970.

This document can be made available in alternative formats on request for a person with a disability.

File Path:			
Document Owner:	Neonatology		
Reviewer / Team:	Neonatal Coordinating Group		
Date First Issued:	July 2006	Last Reviewed:	9 th March 2020
Amendment Dates:		Next Review Date:	9th March 2023
Approved by:	Neonatal Coordinating Group	Date:	24 th March 2020
Endorsed by:	Neonatal Coordinating Group	Date:	
Standards Applicable:	NSQHS Standards:  		
Printed or personally saved electronic copies of this document are considered uncontrolled			