



GUIDELINE

Pyloric Stenosis: Infantile Hypertrophic

Scope (Staff):	Nursing and Medical Staff
Scope (Area):	NICU KEMH, NICU PCH, NETS WA

Child Safe Organisation Statement of Commitment

CAHS commits to being a child safe organisation by applying the National Principles for Child Safe Organisations. This is a commitment to a strong culture supported by robust policies and procedures to reduce the likelihood of harm to children and young people.

This document should be read in conjunction with this [disclaimer](#)

Aim

To provide standardized management protocol for neonates with Infantile Hypertrophic Pyloric Stenosis (IHPS).

Risk

Neonates with IHPS may have severe acid-base abnormalities. Failure to prevent and/or manage these abnormalities may increase morbidities in neonates.

Background

IHPS is a disorder presenting in infants due to hypertrophy of the pylorus leading to partial or complete gastric outlet obstruction. The incidence is 2 to 3 per 1000 live births.

Etiology

- Unclear, considered multifactorial, family history (48% siblings have h/o IHPS)
- First born children (RR:1.23; 95% CI: 1.07-1.4)
- Male gender (M:F 4:1; RR:2.71; 95% CI:1.93-3.78), higher in preterm females
- Neonatal hypergastrinemia and increased gastric acidity
- Exposure to Erythromycin and Azithromycin in the first 6 weeks of life
- Formula fed > breast fed
- Maternal smoking (RR:1.75; 95% CI: 1.54-2), young maternal age

- Co-morbid with congenital heart disease

Presentation

Classically infants present between 3 to 6 weeks of age. Occasionally they may present in the first 2 weeks or later than 6 weeks of age, especially in premature babies.

Recurrent vomiting soon after feeds. Typically, the vomiting is described as projectile, non-bilious and happens soon after feeds. The baby is generally very hungry and wants to feed despite recurrent vomiting. Some infants, rarely, can present with bilious vomiting. There may be weight loss and signs of dehydration on clinical examination. It is important to elicit history of wet nappies. Abdominal palpation may reveal the presence of an “olive mass” in the right upper quadrant but is less commonly seen now a days because of early diagnosis. A recent systematic review reported that palpation has limited sensitivity in diagnosing IHPS.

Blood gas findings

- Hypochloraemic metabolic alkalosis with hypokalaemia, not typical in preterm
- Measure urea and creatinine levels on admission. It will help when deciding commencement of potassium infusion.

Special consideration for prematurity: Premature babies with IHPS can present well before the infant even becomes a “term baby”. The characteristic projectile vomiting, VGP and metabolic alkalosis, and palpable pyloric olive (despite thin abdominal wall) are usually absent in preterm infants with IHPS. Hence early ultrasonogram and or complementary upper GI contrast study must be done to confirm or refute the presence of IHPS in a preterm.

Prolonged medical treatment associated with delayed diagnosis and malnutrition increase the postoperative complications and recovery time which is due to physiological immaturity of the organs and LBW of a preterm rather than IHPS. Early surgical intervention can decrease the morbidity and mortality. IHPS should always be considered in the differential diagnoses in a preterm with feed intolerance, GORD, or recurrent vomiting.

Diagnosis

Ultrasonography is the diagnostic modality of choice, and it shows hypertrophied and elongated pylorus. (Figure 1a). Upper GI contrast (Fig 1b: string-sign) may be performed if ultrasonography is inconclusive or if associated gut anomalies are clinically suspected.

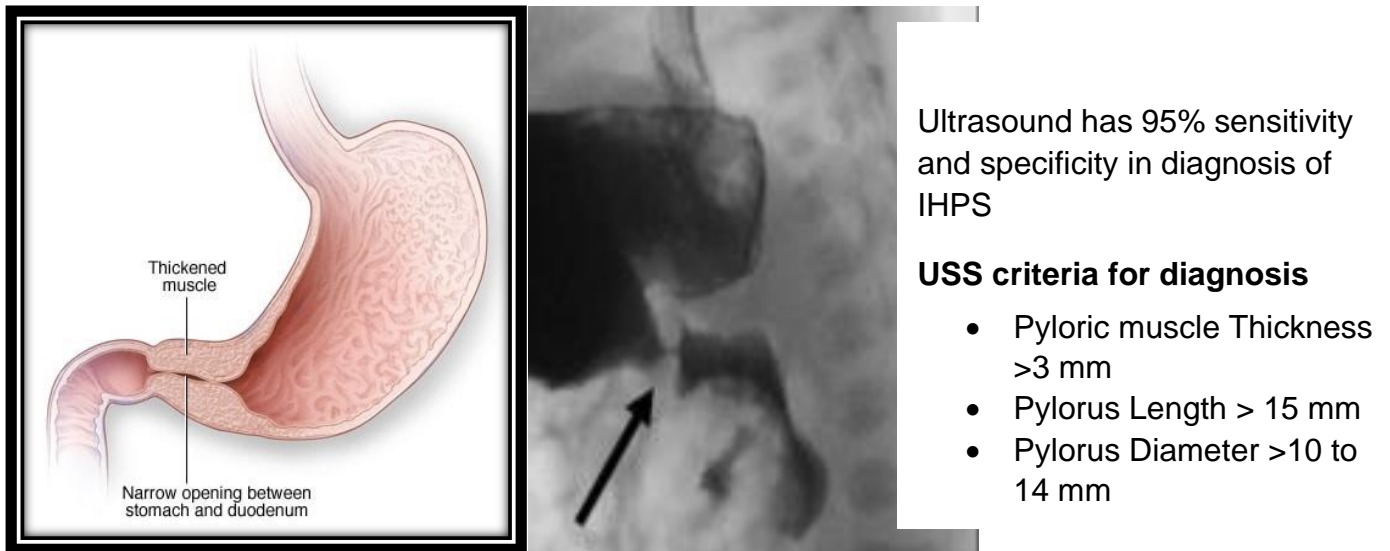


Fig 1a. Showing Thickening of the pylorus muscle and hypertrophy causing Gastric outlet obstruction.
Fig 1b. Narrowed pyloric canal on upper GI contrast (String-sign)

Immediate management

- Admit to hospital, NICU/Paediatrics ward based on age, gestation and weight criteria for admission.
- Keep nil by mouth.
 - Continuing feeding should be discussed with surgeons in case of equivocal diagnosis on ultrasound.
- Insert size 8F nasogastric tube and allow it to drain freely.
- Arrange an ultrasound of the abdomen: diagnostic modality of choice.
- If USG is inconclusive and clinical suspicion persists, upper GI contrast could be considered in consultation with surgeons (especially in preterm infants).
- Insert intravenous cannula. Send blood investigations - venous blood gas (VBG), UEC, FBC, Cross match.
- Measure urea and creatinine levels on admission. It will help when deciding commencement of potassium infusion.
- Start antibiotics consider differential diagnosis such as sepsis, UTI, volvulus, NEC especially in preterm infant, gastroesophageal reflux disease etc.
- Assess the degree of dehydration and fluid management:
 - Management of dehydration and metabolic alkalosis with fluid resuscitation (Refer to Figure 2)
 - The fluid management is generally guided by the severity of dehydration and the blood gases and electrolyte abnormality (Figure 2)

- Nasogastric fluid losses should be replaced mL for mL every 4 hours with 0.9% Sodium Chloride.
- Correct hypokalaemia if present (Refer to Figure 2). Ensure that urine output is adequate and creatinine levels are normal before commencing potassium infusion.
- Monitor blood glucose levels, if <3 mmol/L, increase the glucose infusion rate.

Surgical management

- The definitive management of IHPS is Laparoscopic or open Ramstedt's pyloromyotomy.
- It is preferable to correct alkalosis prior to surgery to decrease the risk of post-operative apnoea's. Preferable pre-operative blood gases targets:
 - Ph <7.45 , Base excess <3 , Bicarbonate < 26 mmol/L, Sodium >132 mmol/L, Chloride > 100 mmol/L and Potassium > 3.5 mmol/L, Blood glucose >3.5 mmol/L.

Note: This may not be achievable in all cases and need to be considered in discussion with surgeons.

Post-operative care

- Monitor the baby for apnoea for at least 24 hours post-surgery.
- Cease antibiotics post-operatively unless otherwise specified.
- Some infants may have post-op Gastroesophageal reflux or vomiting which should be managed on case-to-case basis.

Post-operative feeding guide

Feeds can generally be started after 4 hours unless specified in the operation notes. Adjusting the IV fluid rate as oral feeds are tolerated.

Feeds are usually tolerated by 24 hours post operatively.

This is a guide only and will need to be adjusted if vomiting persists.

- Feeding:
 - Feeds can generally be started after 4hours unless specified in the operation notes and post-operative instructions.
 - Adjusting the IV fluid rate as oral feeds are tolerated.
 - Start 2 or 3 hourly feed as per the gestation and weight of the baby.
 - Generally, all infant will tolerate starting feed at 5 ml 3 hourly feed
 - Grade up feeds 5ml every 3 hours.

- Breast feeding can be commenced 3 hourly for 5 to 10 minutes in addition as per parental preferences.
- Transition to full breast feed gradually with the grading up of feeds.
- Full feeds can be graded as tolerated over 24 hours unless other concerns exist, requires clinician discretion. Majority will tolerate full feeds.

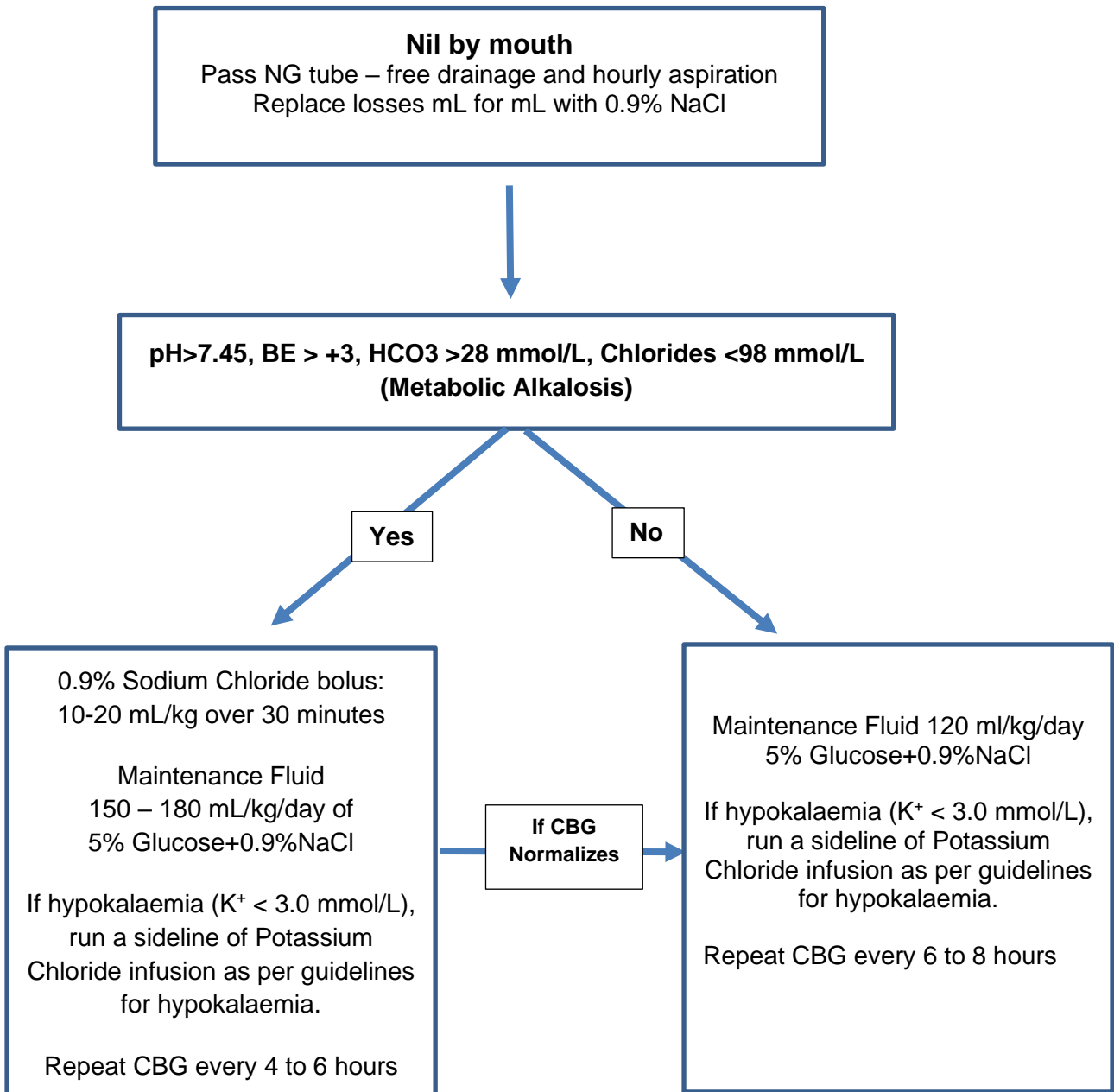


Fig 2: Management of Initial fluid resuscitation based on CBG results

TPN should be avoided in the initial rehydration and stabilization phase

Related CAHS internal policies, procedures and guidelines

Neonatology Clinical Guidelines

- [Post-Operative Care](#)
- [Pre-Operative Care](#)



References

1. Obaid YY et al. Perinatal risk factors for infantile hypertrophic pyloric stenosis: A systematic review and meta-analysis. J Pediatr Surg. 2022 Aug 24:S0022-3468(22)00552-8.
2. van den Bunder FA et al,. Diagnostic accuracy of palpation and ultrasonography for diagnosing infantile hypertrophic pyloric stenosis: a systematic review and meta-analysis. Br J Radiol. 2022 Oct 1;95(1139):20211251.
3. Danko ME, Evans PT, Upperman JS. Current management of pyloric stenosis. Semin Pediatr Surg. 2022 Feb;31(1):151145.
4. Almaramhy, H.H., Al-Zalabani, A.H. The association of prenatal and postnatal macrolide exposure with subsequent development of infantile hypertrophic pyloric stenosis: a systematic review and meta-analysis. Ital J Pediatr 45, 20 (2019).
5. Kapoor R, Kancherla V, Cao Y, et al. Prevalence and descriptive epidemiology of infantile hypertrophic pyloric stenosis in the United States: A multistate, population-based retrospective study, 1999-2010. Birth Defects Res 2019; 111:159.
6. Taylor ND, Cass DT, Holland AJ. Infantile hypertrophic pyloric stenosis: has anything changed? J Paediatr Child Health. 2013 Jan;49(1):33-7. Epub 2012 Dec 2.
7. Kumar, T. R. and C. Srikanth (2014). "Infantile hypertrophic pyloric stenosis in an extremely preterm male twin; a case report and review." J Indian Assoc Pediatr Surg 19(3): 184-185.

Useful resources

[Laparoscopic Pyloromyotomy \(child\)](#)

This document can be made available in alternative formats on request.

Document Owner:	Neonatology		
Reviewer / Team:	Neonatology Coordinating Group / Surgical Services		
Date First Issued:	December 2022	Last Reviewed:	December 2022
Amendment Dates:		Next Review Date:	December 2025
Approved by:	Neonatology Coordinating Group	Date:	24 th January 2023
Endorsed by:	Neonatology Coordinating Group	Date:	
Standards Applicable:	NSQHS Standards:   Child Safe Standards: 1,10		

Printed or personally saved electronic copies of this document are considered uncontrolled



Healthy kids, healthy communities

Compassion
Excellence
Collaboration
Accountability
Equity
Respect

Neonatology | Community Health | Mental Health | Perth Children's Hospital