



**GUIDELINE**

**Ventricular Dilatation**

<b>Scope (Staff):</b>	Nursing and Medical Staff
<b>Scope (Area):</b>	NICU KEMH, NICU PCH, NETS WA

**Child Safe Organisation Statement of Commitment**

CAHS commits to being a child safe organisation by applying the National Principles for Child Safe Organisations. This is a commitment to a strong culture supported by robust policies and procedures to reduce the likelihood of harm to children and young people.

This document should be read in conjunction with this [disclaimer](#)

**Contents**

Aim ..... 2

Risk..... 2

Post-Haemorrhagic Ventricular Dilatation (PHVD) ..... 2

    Pathophysiology ..... 2

    Management ..... 2

Ventricular Tap ..... 6

    Equipment & Procedure ..... 6

Ventriculoperitoneal (VP) Shunt or CSF Reservoir Insertion ..... 7

    Key Points ..... 7

    Shunt Characterisation ..... 8

    Pre-Operative Investigations and Management ..... 8

    Intra-Operative Management..... 8

    Post-Operative Management..... 8

## Aim

To improve monitoring of ventricular dilatation and reduce the risk of trauma to the brain and iatrogenic Cerebrospinal Fluid (CSF) infection.

## Risk

Ventricular dilatation is associated with a high risk for poor motor and cognitive neurodevelopmental outcomes including increased risk of cerebral palsy, epilepsy, sensory deficits, deafness, blindness in infancy and childhood persisting into adulthood as intellectual impairment, memory deficits and behavioural issues.

## Post-Haemorrhagic Ventricular Dilatation (PHVD)

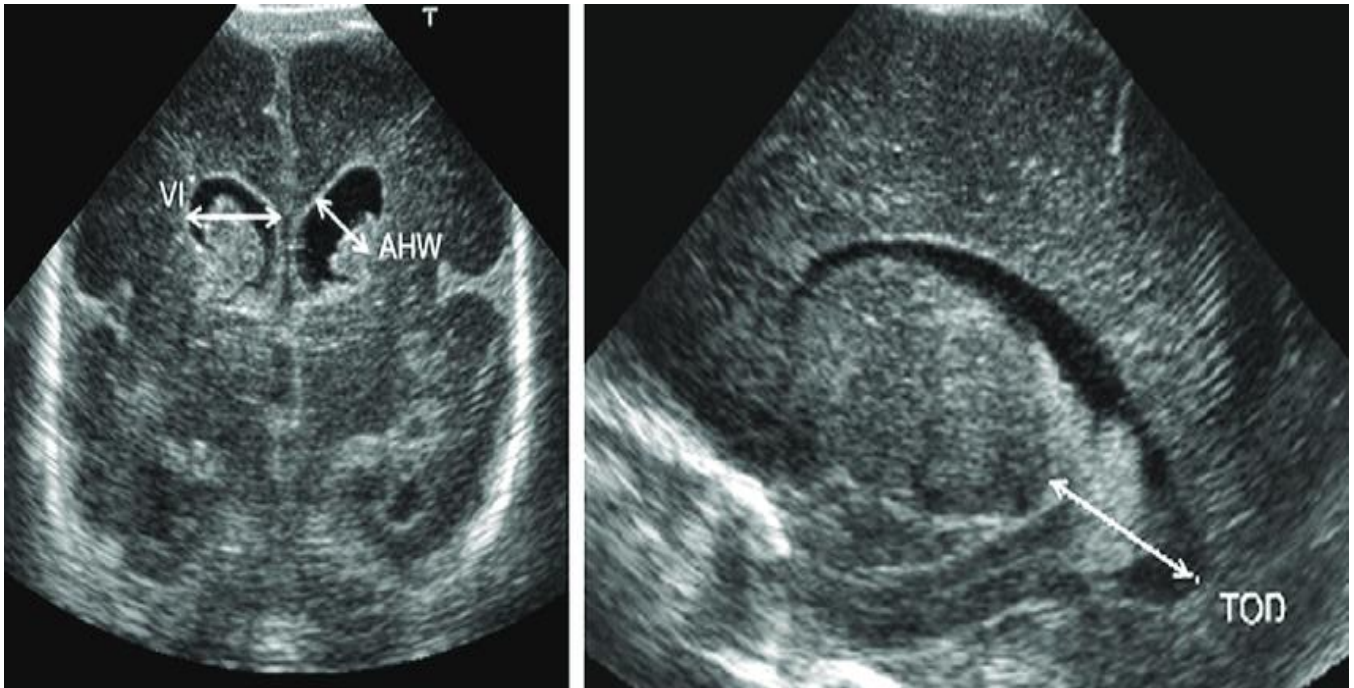
PHVD represents progressive ventricular dilatation following severe intraventricular haemorrhage (IVH), i.e. grade 3 and 4.

## Pathophysiology

Severe IVH (grades 3 and 4) is seen in approximately 15% of extremely preterm infants. More than half of these infants can subsequently develop PHVD. PHVD also encompasses other terms, such as post-haemorrhagic hydrocephalus. PHVD has multiple mechanisms, such as cerebral ischemia, mechanical distortion and neuroinflammation, by which it causes deleterious effects on the preterm infant's brain. Due to an imbalance in CSF production and reabsorption, the ventricles may dilate around 7–14 days. PHVD can progress slowly or rapidly. In infants with slow progression, stabilisation or regression occurs in 65%. In 30–35% of infants, there is a rapid progression in ventricular size over days to weeks.

## Management

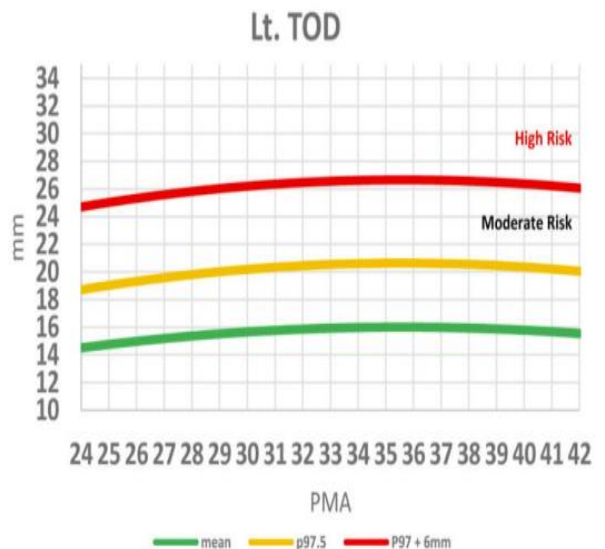
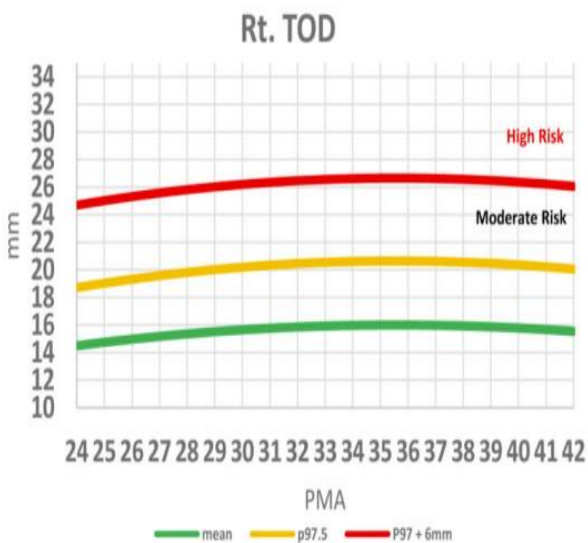
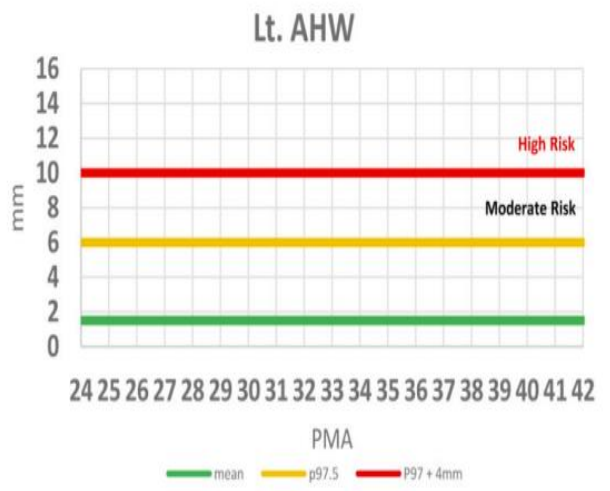
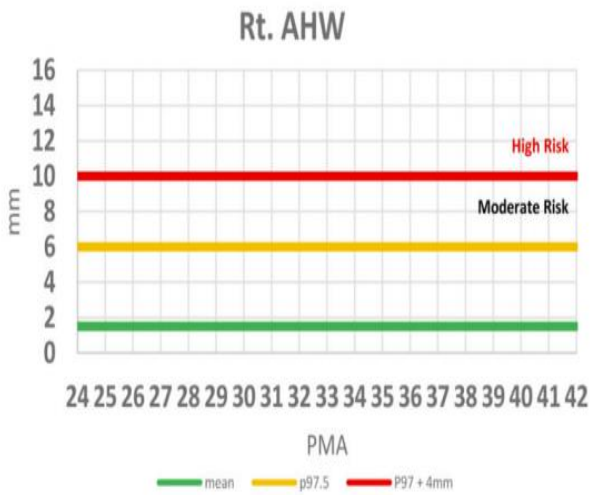
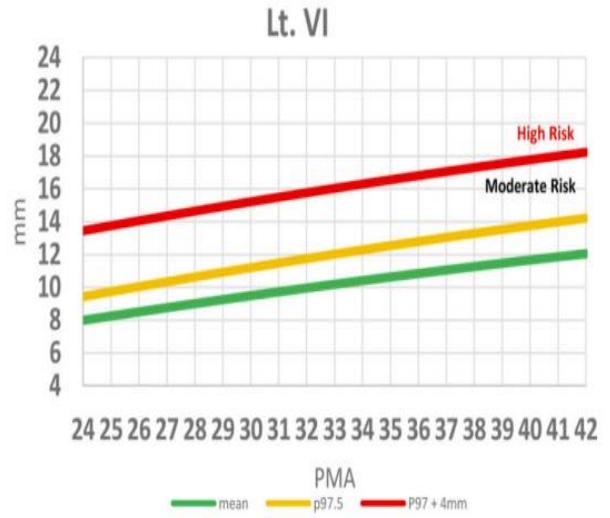
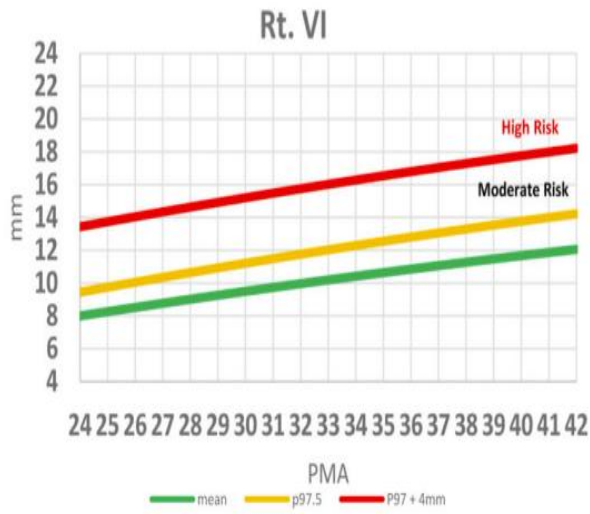
- Bedside cranial ultrasound (CUS) is the modality used to diagnose PHVD. Our routine cranial US screening involves CUS on days of life 1, 7 and 28 in those born at a gestation <32 weeks.
- The most commonly used CUS indices are the “Ventricular Index” (VI), “Anterior Horn Width” (AHW) and Thalamo-Occipital Distance (TOD).
- VI is the distance between the midline (falx) and the lateral border of the lateral ventricle at the level of foramen of Monro (Figure).
- AHW is also measured in the coronal view just anterior to the thalamic notch (Figure).
- TOD measures the occipital horn in the parasagittal plane and is of additional value because there can be a discrepancy in size between the anterior and occipital horns of the lateral ventricle. (Figure). The AHW and TOD measures indicate the ‘ballooning’ shape of the lateral ventricles, and correlate best with 3-dimensional volumetric ultrasound measurements.

**Fig: CUS showing measurement of VI, AHW and TOD**

- The indices measured (in mm) then should be plotted on the percentile charts depicted below as per the day of life on the x-axis. There are 3 lines in these percentile charts.
  - The green line is the mean index for that day of life.
  - The yellow line is at the **97<sup>th</sup> centile** for that index.
  - The red line is at the **97<sup>th</sup> centile +4 mm** for that index.
- Depending on the plot as per the day of life, the index would fall into either the GREEN, YELLOW, or RED ZONES.
  - Green zone: Refers to the part of the graph below the yellow line
  - Yellow zone: Refers to the part of the graph between the yellow and the red lines
  - Red zone: Refers to the part of the graph above the red line

Name:  
DOB:

## Ventricular Measurement Risk Zones



RISK ZONES	IDENTIFICATION	INTERVENTION
<p><b>Low-risk</b> <b>Green zone</b></p> <p>(Refers to the part of the graph below the yellow line)</p>	<p>Infants with IVH with VI <math>\leq</math> 97th percentile, AHW <math>\leq</math> 6 mm and TOD <math>\leq</math> 20 mm.</p> <ul style="list-style-type: none"> <li>• And Absence of the following <b>clinical</b> criteria (rapid increased in HC <math>&gt;</math>2 cm per week, separated sutures or bulging fontanelles) and evidence of PHVD</li> <li>• And No clinical signs of increased intracranial pressure (ICP).</li> </ul>	<p>Monitor closely (weekly head circumference) If associated with severe IVH (grades 3 and 4) and ventricular dilatation, then request for cranial ultrasound (CUS) at least twice weekly.</p> <p>This should be done until the ventricles are stable for 2 weeks and then CUS every 2 weeks until 34 weeks PMA.</p> <p>Arrange Term equivalent MRI (TE-MRI).</p>
<p><b>Moderate-risk</b> <b>Yellow zone</b></p> <p>(Refers to the part of the graph between the yellow and the red lines)</p>	<p>Infants with IVH and VI between 97th percentile and 97<sup>th</sup> percentile +4 mm, AHW between 6mm and 10mm and /or TOD between 20mm and 25 mm.</p> <ul style="list-style-type: none"> <li>• And Absence of the following <b>clinical</b> criteria (rapid increase in HC <math>&gt;</math>2 cm per week, separated sutures or bulging fontanelles) and evidence of PHVD</li> <li>• And No clinical signs of increased intracranial pressure (ICP).</li> </ul>	<p>Monitor closely (weekly head circumference) Neurosurgery and Neurology referral. Shared decision-making for further intervention is required between Neonatology, Neurosurgery and Neurology.</p> <p>CUS at least twice weekly until ventricles are stable for 2 weeks and every 1-2 weeks till 34 weeks GA</p> <p>Arrange for TE-MRI</p> <p>May benefit from LPs 2-3 times done over 1 week, aiming for removing 10 ml/kg of CSF, if the infant is hemodynamically stable.</p> <p>LP not to be performed <math>&gt;</math> 1 time/day</p>
<p><b>High-risk</b> <b>Red zone</b></p> <p>(Refers to the part of the graph above the red line)</p>	<p>Infants with VI <math>&gt;</math>97th percentile +4mm, AHW <math>&gt;</math>10 mm and TOD <math>&gt;</math>25 mm.</p> <ul style="list-style-type: none"> <li>• And/or Infants with <b>clinical</b> criteria (rapid increase in HC <math>&gt;</math>2 cm per week, separated sutures or bulging fontanelles) and evidence of PHVD</li> <li>• And/or Clinical signs of increased intracranial pressure (ICP).</li> </ul>	<p>Monitor closely (weekly head circumference) Urgent Neurosurgery and Neurology referral Shared decision-making for further intervention is required between Neonatology, Neurosurgery and Neurology.</p> <p>CUS at least twice weekly until ventricles are stable for 2 weeks and every 1-2 weeks. Arrange for TE-MRI</p> <p>May benefit from 2-3 LPs done over 1 week, aiming for removing 10 ml/kg of CSF, if the infant is hemodynamically stable. LP not to be performed <math>&gt;</math> 1 time/day Planning for temporizing/definitive neurosurgical interventions if serial LPs are not effective.</p>

- The onus to request for additional CUS (outside the routine) shall be with the treating neonatal team at KEMH and PCH NICU's. Most of these scans should be organized during the working days and hours in the week.
- The need to do any additional scans on weekend/public holidays/after-hours that can alter the management should be discussed by the neonatal consultant with the neurosurgical and radiology consultant.

## Ventricular Tap

A ventricular tap is indicated to:

- Draining cerebrospinal fluid in non-communicating hydrocephalus
- Diagnose ventriculitis.
- Administering intraventricular drugs.

A ventricular tap is performed by medical staff deemed competent in the procedure and is a surgical aseptic procedure. **It is usually done by the neurosurgeons. Please discuss with the neurosurgeons if an infant requires a ventricular tap.**

Prior to a ventricular tap, an ultrasound should be performed to confirm ventriculomegaly and measurements taken to confirm the depth and direction of needle insertion. Refer to [Ventriculoperitoneal \(VP\) Shunt or CSF Reservoir Insertion](#) guideline for further information on management.

## Equipment & Procedure

- Shave pack / Skin prep as per gestation
- Sterile drapes / Dressing pack
- Lumbar puncture needle (size 22G or 23G)
- Specimen bottles - appropriate bottles for specific tests

Procedure
1. The infant must have continuous monitoring and have resuscitation equipment at hand.
2. Sucrose can be given for analgesia
3. Shave the scalp overlying the lateral angle of the anterior fontanelle taking care not to injure the skin.
4. Clean a wide area of the head with appropriate solution. <a href="#">Aseptic Technique</a>
5. Position the infant supine with the top of the infant's head facing toward the operator.

Procedure
6. With left hand index and thumb, move skin over point of entry such that when tap done and the needle is removed, the skin moves back to original position and the track of the needle is broken.
7. Insert the spinal needle into the lateral angle of the fontanelle and advance it toward the inner angle of the ipsilateral eye. The needle should be inserted smoothly without change of direction to minimise trauma to the brain.
8. Once the ventricle has been penetrated, the stylet is removed, and the CSF should drip out rather than be aspirated.
9. Once the required amount of CSF is obtained the needle should be removed and pressure applied to the area to prevent leakage of CSF.
10. Clean the area with 1% chlorhexidine and let dry.
11. The infant's tolerance of the procedure should be noted in the infant's progress notes.

## Ventriculoperitoneal (VP) Shunt or CSF Reservoir Insertion

Insertion of a Ventriculoperitoneal (VP) shunt or CSF Reservoir is indicated for the management of infantile hydrocephalus. Hydrocephalus is defined as excess cerebrospinal fluid (CSF) accumulation in the brain due to disturbance of the formation, flow or absorption of CSF. Infantile hydrocephalus is associated with the following:

- Aqueduct Stenosis, Spina Bifida and Chiari II malformation.
- Dandy-Walker syndrome, Encephaloceles, Viral or Parasitic infections, Arachnoid Cysts, Intracranial Neoplasm's and Vascular Problems.
- Perinatal Intraventricular Haemorrhage (IVH) and Meningitis.
- Trauma, closed head injury.

(Intraventricular Haemorrhage, Aqueduct Stenosis and myelomeningocele are the most frequent of these causes).

### Key Points

- Antibiotic prophylaxis with [Vancomycin](#) and [Cefotaxime](#) should be commenced 2 hours prior to surgery and then continued for 48 hours.
- Ensure parents have received education and written information about infection or blockage of shunt and on the care of their infant at home after discharge as this will enable parents to identify the signs of infection and malfunction of the shunt early. [VP shunt – Care at home](#)

## Shunt Characterisation

The VP Shunts that are used are antibiotic impregnated (Rifampicin and Clindamycin). Studies have shown that antibiotic impregnated catheters decrease the risk of CSF shunt infections. Shunts usually consist of three parts:

1. **Proximal end** that is radiopaque and is placed into the ventricle of the brain. This end has multiple small perforations.
2. **Valve** - this allows for unidirectional flow. Some shunts can be adjusted to various opening pressures (called programmable shunts). Usually has a reservoir that allows for checking shunt pressure and sampling CSF.
3. **Distal end** that is placed into the peritoneum by tracking the tubing subcutaneously.

## Pre-Operative Investigations and Management

Preferably start 7 days prior to surgery. However, urgent shunt surgeries should not be postponed for the sake of pre-operative investigations.

Procedure
1. All Infants requiring shunt surgery for open spina bifida must be managed with <b>Latex Free</b> care. Including latex free products i.e. dummies, dressing etc.
2. Screen nasal and any skin lesions for the presence of Methicillin Resistant Staphylococcus aureus (MRSA) and Methicillin Sensitive Staphylococcus Aureus (MSSA) Consult with a clinical microbiologist if results are positive before proceeding to surgery.
3. Decolonisation process: Pre-operative chlorhexidine wash with 1% chlorhexidine and Mupirocin 2% nasal ointment to be attended prior to theatre. See <a href="#">Chlorhexidine Wash Procedure &amp; Pre-Operative Care</a>
4. Two hours prior to surgery, administer IV <a href="#">Vancomycin</a> 15 mg/kg and <a href="#">Cefotaxime</a> IV 50 mg/kg

## Intra-Operative Management

During surgery, after induction of anaesthesia, ensure that Vancomycin has been completed and flushed through the line. Then administer IV [Cefotaxime](#) 50 mg/kg. If Vancomycin has not been administered pre-operatively, reverse the order of antibiotics given. Intra-operative antibiotics have been shown to reduce the risk of shunt or reservoir infections.

## Post-Operative Management

Also refer to [Post-Operative Handover](#) and [Post-Operative Care](#) guidelines.



Specific Care
1. Continue antibiotics for 48 hours post-operatively, give 8 hourly <a href="#">Cefotaxime</a> 50 mg/kg. First dose to be given 8 hours post the administration of the intra-operative dose.
2. Administer IV <a href="#">Vancomycin</a> at 15 mg/kg/dose 8 hourly irrespective of gestation. First dose to be given 8 hours post the administration of the intra-operative dose.
3. Hourly neurological observations for 24 hours to be commenced on return to the unit. Use MR494 Neonatal Neurological Observations Chart.
4. Ensure head and abdominal dressings remain dry and intact. Observe for the accumulation of CSF beneath the skin leading to soft 'boggy' swelling near the surgical wound on the scalp. A CSF leak or blockage is associated with the increased risk of shunt infection. If swelling is noted, call the neurosurgeon for review immediately
5. Scalp and abdominal dressings are to be taken down 48-72 hours post-surgery. Remove the dressings only after discussing with the neurosurgeons. Dressings can be removed earlier if the wound is soaked through with blood or there is concern for the wound.
6. After the dressing is removed, clean the area surrounding the surgical sites with 1% chlorhexidine wipes three times a day for three days or until discharged (if before 3 days). To minimise the colonisation of bacteria near the surgical wound.
7. Keep the wound dry for 7 days. Sponging around the area is allowed, if the wound becomes wet then, dry off immediately. If the dressing becomes wet, then change the dressings. All sutures are dissolvable.
8. Continue with Latex Free care if indicated.

Related CAHS internal policies, procedures, and guidelines
<p>Neonatal Clinical Guidelines</p> <ul style="list-style-type: none"> <li>• <a href="#">Aseptic Technique in the Neonatal Unit</a></li> <li>• <a href="#">Chlorhexidine Wash Procedure</a></li> <li>• <a href="#">Post-Operative Care</a></li> <li>• <a href="#">Post-Operative Handover</a></li> <li>• <a href="#">Pre-Operative Care</a></li> <li>• <a href="#">Neonatology Medication Protocols</a></li> </ul>

## References and related external legislation, policies, and guidelines


**Post Haemorrhagic Ventricular Dilatation**

- Levene MI, Starte DR. A longitudinal study of post-haemorrhagic ventricular dilatation in the newborn. *Arch Dis Child*. 1981;56:905–10. [PubMed: 7332337]
- Davies MW, Swaminathan M, Chuang SL, Betheras FR. Reference ranges for the linear dimensions of the intracranial ventricles in preterm neonates. *Arch Dis Child Fetal Neonatal Ed*. 2000;82:F218–23. [PubMed: 10794790]
- Brouwer MJ, De Vries LS, Groenendaal F, Koopman C, Pistorius LR, Mulder EJH, et al. New reference values for the neonatal cerebral ventricles. *Radiology*. 2012;262:224–33. [PubMed: 22084208]
- Benavente-Fernandez I, Lubian-Gutierrez M, Jimenez-Gomez G, Lechuga-Sancho AM, LubianLopez SP, Neonatal Neurology F. Ultrasound lineal measurements predict ventricular volume in posthaemorrhagic ventricular dilatation in preterm infants. *Acta Paediatr*. 2017;106:211–7. [PubMed: 27783429]
- El-Dib M, Limbrick DD Jr, Inder T, Whitelaw A, Kulkarni AV, Warf B, Volpe JJ, de Vries LS. Management of Post-hemorrhagic Ventricular Dilatation in the Infant Born Preterm. *J Pediatr*. 2020 Nov;226:16-27.e3. doi: 10.1016/j.jpeds.2020.07.079. Epub 2020 Jul 30. PMID: 32739263; PMCID: PMC8297821.
- de Vries LS, Groenendaal F, Liem KD, Heep A, Brouwer AJ, van 't Verlaat E, Benavente-Fernández I, van Straaten HL, van Wezel-Meijler G, Smit BJ, Govaert P, Woerdeman PA, Whitelaw A; ELVIS study group. Treatment thresholds for intervention in posthaemorrhagic ventricular dilation: a randomised controlled trial. *Arch Dis Child Fetal Neonatal Ed*. 2019 Jan;104(1):F70-F75. doi: 10.1136/archdischild-2017-314206. Epub 2018 Feb 10. PMID: 29440132.

**Ventriculoperitoneal (VP) Shunt or CSF Reservoir Insertion**

- Bernardo O Ratilal, João Costa, Cristina Sampaio. Antibiotic prophylaxis for surgical introduction of intracranial ventricular shunts. *Cochrane library*; 2006
- Tamburrini G, Frsassanito P, Jakavaki K et al. Myelomeningocele: the management of the associated hydrocephalus. *Child's Nervous System* 2013 Sep;29(9):1569-79
- Thomas R, Lee S, Patole S, Rao S. Antibiotic-impregnated catheters for the prevention of CSF shunt infections: a systematic review and meta-analysis. *Br J Neurosurg*. 2012 Apr;26(2):175-84.
- Zhou WX et al Systematic Review and Meta-Analysis of Antibiotic-Impregnated Shunt Catheters on Anti-Infective Effect of Hydrocephalus Shunt. *J Korean Neurosurg Soc*. 2021 Mar;64(2):297-308.
- Mallucci CL et al. Silver-impregnated, antibiotic-impregnated or non-impregnated ventriculoperitoneal shunts to prevent shunt infection: the BASICS three-arm RCT. *Health Technol Assess*. 2020 Mar;24(17):1-114.
- Klimo P Jr, Van Poppel M, Thompson CJ et al; Pediatric Hydrocephalus Systematic Review and Evidence-Based Guidelines Task Force. Pediatric hydrocephalus: systematic literature review and evidence-based guidelines. Part 6: Preoperative antibiotics for shunt surgery in children with hydrocephalus: a systematic review and meta-analysis. *J Neurosurg Pediatr*. 2014 Nov;14 Suppl 1:44-52. doi: 10.3171/2014.7.PEDS14326.
- Jaeger W, Lee S, Vineet D, Keil A, Agarwal N, Rao S. Ventriculoperitonealshunts in neonates: a retrospective study of outcomes with antibiotic-impregnated catheters and a modified peri-operative antibiotic protocol. *Br J Neurosurg*. 2017 Dec;31(6):672-676.

This document can be made available in alternative formats on request.

Document Owner:	Neonatology		
Reviewer / Team:	Neonatology Coordinating Group / Neurosurgery		
Date First Issued:	July 2006	Last Reviewed:	July 2023
Amendment Dates:	Combined guidelines on Ventricular Tap and Ventriculoperitoneal (VP) Shunt or CSF Reservoir Insertion and added NEW content on Post Haemorrhagic Ventricular Dilatation. Renamed Ventricular Dilatation	Next Review Date:	July 2026
Approved by:	Neonatology Coordinating Group	Date:	22 <sup>nd</sup> August 2026
Endorsed by:	Neonatology Coordinating Group	Date:	
Standards Applicable:	NSQHS Standards:  Child Safe Standards: 1,10		

Printed or personally saved electronic copies of this document are considered uncontrolled



**Healthy kids, healthy communities**

Compassion
Excellence
Collaboration
Accountability
Equity
Respect

Neonatology | Community Health | Mental Health | Perth Children's Hospital